infarction in 2010, hypertension, and type 2 diabetes mellitus. For 3 years, her home medications included aspirin, metoprolol, furosemide, insulin, and dabigatran. At a follow-up cardiological visit, dabigatran was replaced with edoxaban because of renal failure (creatinine clearance, 20 mL/min). After 10 days of starting edoxaban, the patient developed a raised, pruritic, maculopapular rash involving the trunk and proximal extremities; the severity was mild to moderate. Edoxaban therapy was stopped and topical corticosteroid treatment was prescribed, with complete resolution within 2 weeks. Given the fragility of the patient, no challenge test with an alternative DOAC was performed, and warfarin was prescribed by the cardiologist for anticoagulation.

A 60-year-old man with a 7-year history of NVAF treated with rivaroxaban was referred to our unit. However, 6 months previously, he had temporarily stopped rivaroxaban for selective orthopedic surgery. Approximately 1 week after restarting the drug, he developed a pruritic rash, and the cardiologist replaced rivaroxaban with edoxaban, without a substantial clinical improvement. At the time of our visit, the patient presented with a diffuse, pruritic maculopapular rash, more pronounced on the trunk, and facial erythema. Laboratory test results, including autoantibodies (ie, antinuclear, antidouble-stranded DNA, anti-extractable nuclear antigen antibodies), were all within normal ranges. The clinical course was favorable, with progressive resolution of exanthema 2 weeks after the initiation of corticosteroids and discontinuation of edoxaban therapy. Approximately 2 weeks later, a graded challenge test with an alternative DOAC (apixaban) was performed and tolerated. The patient is still taking the drug.

In these patients, the clinical features, timing between the start of therapy and the onset of reaction (7-15 days), and resolution of the rash upon discontinuation of edoxaban treatment are strongly compatible with a delayed-type DHR.[9] Applying both causality scales (the World Health Organization–Uppsala Monitoring Centre and the Naranjo scale), a causal relationship between taking edoxaban and the adverse cutaneous reaction resulted “probable” in all 3 cases.

Drug provocation test with the suspected culprit was not considered appropriate or clinically necessary in these patients. Switching to another alternative DOAC was possible (patients 1 and 3), even if cross-reactivity might have occurred (patient 3). Given the rarity of cases and the lack of evidence, it is not currently possible to better define cross-reactions and preferential switches at the moment. Nevertheless, a diagnostic algorithm, including patch testing, for DHR to DOAC has been previously proposed.[3,5]

In conclusion, the aforementioned described suspected DHR to edoxaban presented the following similar hallmarks to those of other DOACs, as reported in the literature and in our experience[5]: most frequently, delayed-type reactions, particularly T-cell mediated, and mild to moderate in severity.

These 3 cases highlight the importance of raising clinicians’ awareness on the risk of immune-mediated reactions to edoxaban, which might still be underestimated. Patch tests may be used in the future to evaluate alternative DOACs and to guide subsequent oral drug tolerance tests in patients with mild delayed hypersensitivity reactions.

Laura Franceschini, MD[*,†]
Giulia Carli, MD[*]
Giancarlo Landini, MD[#]
Daniela Matarrese, MD[§]
Alessandro Farsi, MD[*]
[*]*SOS Allergology and Immunology Unit*
Santo Stefano Hospital
Prato, Italy
[†]*UOC Gastroenterology and Digestive Endoscopy Unit*
Le Scotte Hospital
Siena, Italy
[#]*Department of Internal Medicine*
USL Toscana Centro
Florence, Italy
[§]*Azienda USL Toscana Centro*
Santo Stefano Hospital
Prato, Italy
alessandro.farsi@uslcentro.toscana.it

References

1. Giugliano RP, Ruff CT, Braunwald E, et al. Edoxaban versus warfarin in patients with atrial fibrillation. *N Engl J Med*. 2013;369(22):2093–2104.
2. Hokusai-VTE Investigators, Büller HR, Décousus H, et al. Edoxaban versus warfarin for the treatment of symptomatic venous thromboembolism. *N Engl J Med*. 2013;369(15):1406–1415.
3. Carli G, Farsi A, Chiarini F, Lippolis D, Cortellini G. Hypersensitivity reactions to non-vitamin K oral anticoagulants - a review of literature and diagnostic work-up proposal. *Eur Ann Allergy Clin Immunol*. 2019;51(1):7–14.
4. Cortellini G, Rossi F, Lippolis D, Cortellini F, Gavioli B, Ballardini G. Delayed hypersensitivity to new oral anticoagulants. Demonstration of cross reactivity for the drug category and definition of non-irritant concentrations for patch tests. *Eur Ann Allergy Immunol*. 2019;51(1):38–40.
5. Cortellini G, Carli G, Franceschini L, Lippolis D, Farsi A, Romano A. Evaluating nonimmediate cutaneous reactions to non-vitamin K antagonist oral anticoagulants via patch testing [e-pub ahead of print]. *J Allergy Clin Immunol Pract*. https://doi.org/10.1016/j.jaip.2020.04.05. Accessed May 4, 2020.
6. Demoly P, Kropf R, Bircher A, Pichler WJ. Drug hypersensitivity: questionnaire. EAACI interest group on drug hypersensitivity. *Allergy*. 1999;54(9):999–1003.
7. The Uppsala Monitoring Centre. The use of the WHO-UMC system for standardised case causality assessment. Available at: http://www.who.int/medicines/areas/quality_safety/safety_efficacy/WHOcausality_assessment.pdf. Accessed April 3, 2020.
8. Naranjo CA, Busto U, Sellers EM, et al. A method for estimating the probability of adverse drug reactions. *Clin Pharmacol Ther*. 1981;30(2):239–245.
9. Brockow K, Ardern-Jones MR, Mockenhaupt M, et al. EAACI position paper on how to classify cutaneous manifestations of drug hypersensitivity. *Allergy*. 2019;74(1):14–27.

Successful desensitization of a patient with Fabry disease with agalsidase beta (Fabrazyme) anaphylaxis after omalizumab pretreatment

Check for updates

Fabry disease is a rare lysosomal storage X-linked genetic disorder caused by pathogenic variants in the *α-galactosidase A* gene (*α-Gal A*) resulting in glycolipid accumulation (mainly globotriaosylceramide or globotriaosylsphingosine) within cell lysosomes. Of note, 2 Fabry disease phenotypes in men include a severe form (1:22,570 men) characterized by a reduction in *α-Gal A* activity and accumulation of globotriaosylceramide in vascular endothelial cells, cardiomyocytes, smooth muscle cells, and podocytes, resulting in progressive multiorgan failure and premature death and a milder form (1:1390 men) that develops later in life and is associated with varying levels of *α-Gal A* activity.[1,2]

Disclosures: Dr Bernstein is a principal investigator, consultant, and speaker for Novartis and Genentech. The remaining authors have no conflicts of interest to report.
Funding: The authors have no funding sources to report.

Multiple mutations have been reported for the *α-galactosidase* gene that encodes *α-Gal A* on the X chromosome.[3] However, for both phenotypes, severe localized and systemic inflammation occurs after glycolipids bind to the toll-like receptor 4, are processed, and, then, presented to the T-cell receptors on invariant natural killer T cells (CD1d-restricted T cells) capable of rapidly responding to the lipid antigenic stimulation with release of proinflammatory cytokines (interleukin-1β, tumor necrosis factor-α, and interleukin-6).[4]

Notably, 2 intravenous enzyme replacement therapies, agalsidase alfa (Replagal) and agalsidase beta (Fabrazyme), administered every 2 weeks have been found to slow disease progression and improve patient outcomes, especially if started early in life before organ damage.[5] Agalsidase beta has been reported to be sensitizing, as confirmed by positive skin prick or allergen-specific immunoglobulin E (sIgE) test results, which resulted in approximately 1% of individuals who experienced allergic reactions to receive replacement therapy.[6] Most patients with Fabry disease who previously experienced anaphylaxis have been successfully managed with premedication alone or with recombinant agalsidase beta desensitization.[7,8] Here, we report a case of a patient with adult-onset Fabry disease who developed anaphylaxis to agalsidase beta (Fabrazyme) but failed routine premedication and 3-bag desensitization until omalizumab pretreatment.

A 38-year-old man who was diagnosed as having Fabry disease at the age of 32 years with a history of a severe anaphylactic reaction owing to agalsidase beta infusion presented for an allergy consultation on August 8, 2012. He had been receiving Fabrazyme infusions (75 mg; 1 mg/kg $\times$ 75 kg) every 2 weeks for 5 years without problems until June 22, 2012, when he developed his first anaphylactic reaction. Before this event, he began missing doses or getting half doses of Fabrazyme (32.5 mg) owing to a nationwide medication shortage. However, 3 months (May 8, 2012) before his initial presentation, he again started receiving the full 75 mg dose of Fabrazyme intravenously every 2 weeks. After approximately 6 weeks (June 22, 2012) of treatments, he developed diffuse hives, lip numbness, scratchy throat, itching, and shortness of breath beginning midway through the infusion, which required discontinuation and treatment with epinephrine (0.3 cm^3, 1:1000 intramuscularly), diphenhydramine (100 mg intravenously), and oral prednisone. Approximately 3 weeks (July 18, 2012) after, another Fabrazyme infusion was attempted despite the previous reaction history, and a similar reaction occurred midway through the infusion, which required discontinuation and similar treatment. In the subsequent infusion, a similar reaction occurred despite pretreatment with intravenous diphenhydramine 50 mg and oral acetaminophen 650 mg and a decreased infusion rate. Each reaction occurred after he received 35 mg of Fabrazyme and got progressively worse with severe diffuse hives, chest tightness then associated with audible wheezing, and throat tightness.

During the allergy consultation, spirometry was obtained, revealing a forced expiratory volume in 1 second of 2.95 L (66% predicted) with 12% improvement in postbronchodilators to 3.3 L (78% predicted), consistent with reversible airflow obstruction; his fractional exhaled nitric oxide was elevated at 37 parts per billion (normal, <25 parts per billion). His total IgE was 30.5 KU/L, and aeroallergen sIgE test results were negative. His baseline tryptase level was 4.2 ng/mL. Skin prick testing to undiluted Fabrazyme revealed a 3 mm wheal/9 mm flare reaction. Intracutaneous testing using weight/volume (w/v) dilutions to Fabrazyme revealed an incremental increase in positive skin test reactions (1:100,000 w/v, 5 mm wheal/8 mm flare; 1:10,000 w/v, 9 mm wheal/12 mm flare; 1:1000 w/v, 9 mm wheal/15 mm flare). An enzyme-linked immunosorbent assay, performed following the manufacturer (Sanofi-Genzyme, Cambridge, Massachusetts), for Fabrazyme serum sIgE (no titers provided) and Fabrazyme sIgG (at a 1:6400 titer) was reported to be positive. In Fabrazyme clinical trials, up to 89% of treated patients developed high nonneutralizing sIgG titers within the first 3 months of exposure. These antibodies persist over time but may fluctuate up or down within different individuals. The patient's asthma was treated with a high-dose inhaled glucocorticoid/long-acting beta-agonist combination.

After 1 month, a 3-bag desensitization protocol was attempted with oral glucocorticoids, H1/H2 antagonists, and leukotriene receptor antagonist pretreatment resulting in diffuse hives, severe total body pruritus, and throat tightness after reaching 30 mg of Fabrazyme. Serum tryptase, drawn within 1 hour, was reported to be normal.[9]

After further discussion, rituximab was initiated to reduce or eliminate B lymphocyte-producing Fabrazyme sIgE before Fabrazyme desensitization because it had previously been successfully used for a severe insulin allergic reaction in conjunction with omalizumab.[10] After the patient received 6 rituximab infusions, a 3-bag desensitization was performed resulting in severe pruritic hives after 16 mg of Fabrazyme. Again, the serum tryptase level did not increase.

Subsequently, omalizumab was initiated on the basis of the severe insulin allergy case report.[10] After receiving 5 monthly omalizumab 300 mg subcutaneous injections, a 3-bag desensitization protocol was performed that allowed him to tolerate the full 75 mg Fabrazyme dose without allergic manifestations. He continued receiving biweekly Fabrazyme infusions with monthly omalizumab for 6 months followed by bimonthly injections. A subsequent weight-based adjustment of Fabrazyme to 90 mg was also well tolerated, and he continues to do well with slowed disease progression.

This case represents an index report of a patient with Fabry disease, sensitized to Fabrazyme, who tolerated a 3-bag desensitization protocol only after omalizumab pretreatment. An attempt to induce tolerance to Fabrazyme with rituximab was unsuccessful, which may be related to its inability to remove memory B cells.[11] Conversely, omalizumab may have been successful owing to the blocking of circulating Fabrazyme sIgE antibody and down-regulation of high-affinity IgE Fc epsilon receptor 1 expression on mast cells and basophils. Omalizumab has previously been reported effective for suppressing anaphylactic reactions during aeroallergen, venom, or food immunotherapy, desensitization to aspirin, nonsteroidal anti-inflammatory drugs, insulin, progesterone, and carboplatin. Further investigation is required to better understand the mechanisms of omalizumab as pretreatment for attenuating or preventing severe allergic drug reactions. This case adds to the existing literature by supporting omalizumab use as a pretreatment strategy for the management of severe allergic drug or biologic reactions.

Ilona DuBuske, DO
Kristin Schmidlin, MD
Jonathan A. Bernstein, MD
Division of Immunology/Allergy Section
Department of Internal Medicine
University of Cincinnati College of Medicine
Cincinnati, Ohio
jonathan.bernstein@uc.edu

References

1. Ortiz A, Germain DP, Desnick RJ, et al. Fabry disease revisited: management and treatment recommendations for adult patients. *Mol Genet Metab*. 2018; 123(4):416–427.
2. Matern D, Gavrilov D, Oglesbee D, Raymond K, Rinaldo P, Tortorelli S. Newborn screening for lysosomal storage disorders. *Semin Perinatol*. 2015;39(3): 206–216.
3. Germain DP. Fabry disease. *Orphanet J Rare Dis*. 2010;5:30.
4. Mauhin W, Lidove O, Masat E, et al. Innate and adaptive immune response in Fabry disease. *JIMD Rep*. 2015;22:1–10.
5. Germain DP, Arad M, Burlina A, et al. The effect of enzyme replacement therapy on clinical outcomes in female patients with Fabry disease - a

systematic literature review by a European panel of experts. *Mol Genet Metab*. 2019;126(3):224–235.
6. Möhrenschlager M, Ollert M, Ring J. A study on serum IgE and clinical symptomatology of atopy in patients suffering from the lysosomal storage disorder Fabry disease. *J Eur Acad Dermatol Venereol*. 2008;22(6):692–695.
7. Bodensteiner D, Scott CR, Sims KB, Shepherd GM, Cintron RD, Germain DP. Successful reinstitution of agalsidase beta therapy in Fabry disease patients with previous IgE-antibody or skin-test reactivity to the recombinant enzyme. *Genet Med*. 2008;10(5):353–358.
8. Talreja N, Butt A, Valle RL, Fox RW, Lockey RF. Successful desensitization to agalsidase beta after anaphylaxis. *Ann Allergy Asthma Immunol*. 2014;112(1):71–72.
9. Castells MC, Tennant NM, Sloane DE, et al. Hypersensitivity reactions to chemotherapy: outcomes and safety of rapid desensitization in 413 cases. *J Allergy Clin Immunol*. 2008;122(3):574–580.
10. Yong PF, Malik R, Arif S, et al. Rituximab and omalizumab in severe, refractory insulin allergy. *N Engl J Med*. 2009;360(10):1045–1047.
11. Kaegi C, Wuest B, Schreiner J, et al. Systematic review of safety and efficacy of rituximab in treating immune-mediated disorders. *Front Immunol*. 2019;10:1990.

Novel basophil activation test in the diagnosis of povidone anaphylaxis

Check for updates

Medications generally contain the following 2 components: the active ingredient (intended to produce the desired therapeutic effect) and excipients (inactive ingredients added for purposes such as improving absorption and product stability). Although considered inert, excipients may represent occult allergens capable of causing allergic reactions. To date, 38 excipients have been described to cause symptoms, with an increasing number of reports documenting type 1 hypersensitivity reactions.[1]

Povidone (polyvinylpyrrolidone) is one of the most frequently used excipients found in 35.8% of medications in solid form for oral ingestion.[1] It is a water-soluble synthetic polymer with a molecular weight ranging from 10,000 to 700,000 Da, affecting its viscosity.[2] Cases of povidone anaphylaxis have been described with oral antibiotics, antifungals, local antiseptic, oral paracetamol, oral prednisolone, intra-articular corticosteroid, an ophthalmic preparation, and even in nonmedicinal products including dental fluoride and hair conditioner.[2-5] Most cases were diagnosed with skin testing, with some confirmed using the percentage of histamine release from basophils stimulated with povidone.[2,5] Basophil activation test (BAT) using flow cytometry has now superseded this method, and we report the first povidone allergy case confirmed with this novel assay.

A 53-year-old nonatopic woman had a grade II anaphylactic reaction after hysteroscopy and colposcopy. Aqueous betadine provided procedural skin preparation. The operative period was uneventful, during which she received fentanyl, propofol, and sevoflurane. During recovery, she reported itchy, burning sensations in both feet, though her vital signs were normal. Soon after, she received 1 g of intravenous paracetamol for headache, which began before the procedure. Within 15 minutes, the systolic blood pressure fell to 60 mm Hg, the heart rate dropped to 49 beats per minute, and she became unresponsive. A mild generalized erythematous rash was noted. She was treated immediately with 1.5 L of intravenous crystalloid, atropine, and dexamethasone with rapid improvement. Epinephrine was not administered. Serum tryptase taken shortly after the episode was elevated at 31.6 μg/L, subsequently returning to the reference range (4.7 μg/L) and confirming the clinical diagnosis of anaphylaxis.

Allergy assessment was performed 3 months after the event, in which the patient reported frequent tolerance of oral paracetamol since the procedure. She had negative results to serum specific immunoglobulin E (IgE) against latex, chlorhexidine, and ethylene oxide. The skin prick and intradermal testing (0.02 mL) performed using standardized protocols[6] for fentanyl, thiopentone, propofol and its carrier intralipid, and chlorhexidine yielded negative results. A skin prick test to neat betadine 100 mg/mL (povidone iodine) elicited a 15-mm wheal. However, direct questioning revealed that the patient periodically gargled betadine mouthwash with no ill effects. She also tolerated oral fexofenadine (Telfast, Sanofi-Aventis Australia Pty Ltd, North Sydney, New South Wales, Australia) postoperatively, which contained povidone as an excipient.

The onset of symptoms occurred immediately after the administration of intravenous paracetamol BNM (Boucher and Muir Pty Limited, North Sydney, New South Wales, Australia). This formulation contains 1000 mg/100 mL of paracetamol with excipients of mannitol, povidone, dibasic sodium phosphate dehydrate, and sodium hydroxide in water for injection. Anaphylaxis caused by the excipient mannitol present in intravenous paracetamol preparations has previously been reported,[7] and we undertook skin prick testing to mannitol according to the published concentrations with negative results. Instead, skin prick testing to povidone (Sigma-Aldrich, St Louis, Missouri) at 0.1 g/mL concentration elicited a positive 10-mm wheal and remained positive at a 1:10 dilution with a 6-mm wheal.

Sensitization to povidone was evident, but given the conflicting clinical picture, we sought diagnostic confirmation by means of BAT. The BAT is a quantitative in vitro assay utilizing flow cytometry to assess basophils (CCR3+ cells) after allergen stimulation by detecting CD63 on the cell surface. BAT responses have been reported to correlate with the severity of allergic reactions in patients and exhibit high specificity with low allergen dose.[8] We performed a BAT using a FlowCAST kit (Bühlmann Laboratories AG, Schönenbuch, Switzerland). Whole blood was stimulated with povidone at 8 incremental concentrations. Figure 1 illustrates the clear dose-dependent basophil activation to povidone in our patient, establishing the diagnosis. Basophils from 2 nonallergic controls were not activated at any povidone concentration tested. IgE-dependent (anti-FcεRI) and IgE-independent (N-formyl-methionyl-leucyl-phenylalanine) positive controls induced activation in our patient and in the 2 control participants.

Previous studies have described the utility of BAT for allergy to a range of drugs including beta-lactams, quinolones, neuromuscular

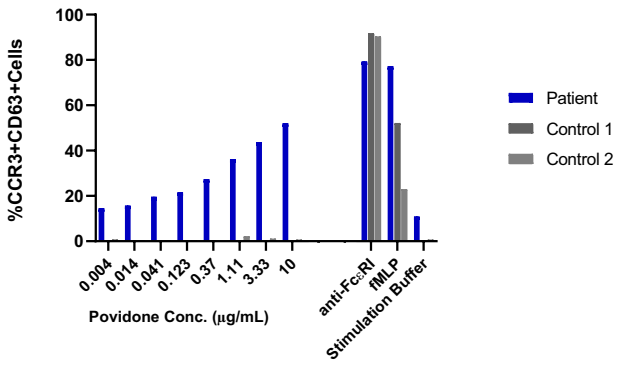

Figure 1. Percentage of activated basophils on stimulation of whole blood with povidone in the patient and 2 control participants. Anti-FcεRI and fMLP were the positive controls, whereas the stimulation buffer was the negative control. Conc., concentration; fMLP, N-formyl-methionyl-leucyl-phenylalanine.

Disclosures: The authors have no conflicts of interest to report.
Funding: The authors have no funding sources to report.