Molecular Genetics and Metabolism Reports 32 (2022) 100896



Contents lists available at ScienceDirect

Molecular Genetics and Metabolism Reports

journal homepage: www.elsevier.com/locate/ymgmr



Case Report



Benefit of 5 years of enzyme replacement therapy in advanced late onset Pompe. A case report of misdiagnosis for three decades with acute respiratory failure at presentation

Mandat Maharaj [a,*], David L. Skidmore [b], Sidney E. Croul [c], David J. Brake [a], Hanns Lochmuller [d]

[a] Cape Breton Regional Hospital, Cape Breton, Nova Scotia, Dalhousie University, Canada
[b] IWK Hospital, Halifax, Nova Scotia, Dalhousie University, Canada
[c] Queen Elizabeth Hospital, Halifax, Nova Scotia, Dalhousie University, Canada
[d] The Ottawa Hospital, Ottawa, Ontario, The University of Ottawa, Canada

ARTICLE INFO

Keywords:
Late onset Pompe disease
Misdiagnosis
Enzyme replacement therapy
Alglucosidase alfa

ABSTRACT

We report on a 57 year old female patient who presented in acute respiratory failure with severe generalized weakness. She was previously misdiagnosed for over three decades as polymyositis. She was treated with enzyme replacement therapy (ERT) for over five years, after being diagnosed with late onset Pompe Disease (LOPD). She returned to independent living with the use of non invasive ventilation at nights. ERT should be considered in the management of patients with advanced LOPD and the effects of ERT closely monitored.

1. Introduction

Pompe Disease is an autosomally recessive, inborn error of metabolism due to Lysosomal Acid-Alpha-Glucosidase deficiency (GAA), discovered by Belgian biochemist, Henri-Gery Hers in 1963. This enzyme normally breaks down glycogen in the acid milieu of lysosomes. GAA deficiency results in lysosomal glycogen accumulation, particularly in cardiac, smooth and skeletal muscles [1,2], with clinical manifestations of progressive myopathy, respiratory weakness and premature death [3]. Pompe Disease was first described in 1932 in a 7 month infant's autopsy by Johannes Cassianus Pompe, a dutch pathologist [1] and is also known as Acid Maltase deficiency and glycogenosis Type II (GSDII) [1,3,4]. The disorder is rare with an estimated frequency of 1/28000 to 1/40000 births [2,5]. The disorder is multi ethnic but has been reported to be less frequent in some populations as in Australians, 1/146000 [6] and more frequent in African Americans (1/14000) as well as Dutch and South East Asians [2]. The GAA gene is located on chromosome 17 with hundreds of pathogenic gene variations identified and most patients are compound heterozygotes [2].

The disease may present across the age spectrum with different phenotypic presentations (Table 1). The differences are mainly due to type of mutation in GAA alleles and variable levels of residual GAA activity [1,6]. Infantile onset Pompe Disease (IOPD) is a severe form involving generalized muscle weakness, hypotonia, hypertrophic cardiomyopathy and respiratory failure. GAA enzymatic activity is absent or <1% [6,7]. If untreated, IOPD invariably results in death before age 1 year old [2–4]. Late onset Pompe Disease (LOPD) includes childhood, juvenile and adult onset disease. It generally presents as limb girdle type weakness, respiratory symptoms particularly shortness of breath, [1–3] and occasionally respiratory failure [6]. Low levels of GAA, <30–40% of normal, are usually found [1,5,7].

LOPD is often a challenging diagnosis clinically and may result in delays in diagnosis for up to 6 years [1,7], range 1–22 in the study by Dasouki [2].

Missed diagnosis or non diagnostic histopathology are not unusual in LOPD and frequently labelled as inflammatory myopathy or non specific findings [4,9], and is not recommended as sole tool of diagnosis [7,8]. With genetically proven Pompe, muscle biopsy may frequently be normal and some authors have recommended this invasive test be avoided [9]. The use of histologic evaluation of muscle biopsy has decreased [8]. Urinary glucose tetrasaccharide (Glc4) is a marker of glycogen storage with variable sensitivity and high specificity in LOPD [7].

Blood based enzyme activity assays as well as enzyme assays in cultured skin fibroblasts and muscle are considered accurate and sensitive [1,6,7]. Dried blood spot (DBSs) screening testing started in 2004, have been recommended and demonstrated recently to be the most frequently used test in diagnosis of Pompe [8,10]. DBSs has led to

* Corresponding author.
E-mail address: Mandat.Maharaj@nshealth.ca (M. Maharaj).

https://doi.org/10.1016/j.ymgmr.2022.100896
Received 9 June 2022; Received in revised form 28 June 2022; Accepted 29 June 2022
Available online 18 July 2022
2214-4269/© 2022 The Authors. Published by Elsevier Inc. This is an open access article under the CC BY-NC-ND license (http://creativecommons.org/licenses/by-nc-nd/4.0/).

Table 1
Subtypes of pompe disease based on severity.

Characteristic	Severe pompe	Less severe pompe
Age of Onset	< 12 months (median < 2 months)	> 12 months to late adulthood (includes childhood, juvenile and adult onset)
Clinical	Classic/Infantile Pompe (IOPD)	Late Onset Pompe Disease (LOPD)
	hypertrophic cardiomyopathy	hypertrophic cardiomyopathy rare, may have conduction abnormalities on EKG
	hypotonia and muscle weakness	progressive proximal limb girdle myopathy
	feeding difficulties and failure to thrive	wheelchair dependency
	rapidly progressive respiratory distress	progressive respiratory failure
	delayed motor development	fatigue
	macroglossia hepatomegaly	cramps
	untreated: survival rare >1 year	untreated: survival variable dependent on: specific mutation, residual GAA activity, possibly genetic factors
GAA Activity	Absent or <1%	<30–40%

Adapted from: Kohler L. et al (Ref. [1])
Van de Ploeg AT. et al. (Ref. [6]).
Tarnopolsky M. et al. (Ref. [16]).

newborn screening and was recommended as part of a screening panel in the US along with a confirmatory algorithm published in 2015 [7]. Genetic testing is increasingly recommended for early confirmation of diagnosis [1,7].

In 2006 enzyme replacement therapy with recombinant alpha glucosidase (Myozyme- Genzyme Corp., Cambridge, MA) was approved by US Food and Drug Administration (FDA) as well as European Medicines Agency, based on pivotal trial results of survival benefit in IOPD [11]. A randomized control trial (RCT), the LOTS Trial and its extension in LOPD, [12,13], demonstrated sustained improvement with ambulation and stable pulmonary function. ERT was subsequently extended for use in LOPD. This study excluded wheelchair bound patients and those requiring invasive respiratory support, which are considered to be "prognostic factors" for survival [3]. A meta analysis of 19 LOPD studies including the single RCT also demonstrated benefit of ERT in improvements in ambulation and respiratory function, as well as survival, between treated and non treated patients [14]. A Dutch study comprising the largest study to date on ERT use in Pompe Disease in adults, confirmed efficacy in LOPD patients treated with ERT up to five years. Nineteen percent of patients with "prognostic factors" were involved in that study [15], but it is unclear if this group of patients benefited from ERT. Generally, expert opinion guidelines are that ERT be "offered" to LOPD patients without severe symptoms, i.e., patients who are not wheelchair bound, and not requiring awake ventilation [16,17]. ERT "may be considered" in the management of patients with severe symptoms, i.e., non ambulatory or patients requiring non-invasive ventilation whilst awake or invasive ventilation, with the caveat of monitoring for benefit [16,17].

We report on our experience with an LOPD patient diagnosed after three decades of progressive symptoms. She was initially mis-diagnosed as polymyositis. Her presentation was that of acute respiratory failure, requiring supportive intensive care management. She was subsequently wheelchair bound and required non-invasive ventilation at night. She was treated with ERT (Myozyme) over five years with sustained ambulatory benefit to date.

2. Case report

A 57 year old Caucasian Northern European non consanguineous female presented to the emergency room (ER) with a six month history of progressive generalized weakness, dysphagia, and increasing rest dyspnea, orthopnea, with marked deterioration two weeks prior to presentation. She reported being symptomatic of limb girdle weakness since her mid 20's and carried a diagnosis of "probable polymyositis" at age 26, after being assessed by neurology and a muscle biopsy performed. She received treatment with oral Cyclophosphamide and Prednisone for about a year. Over the last fifteen years, she was seen by four further neurologists with two further muscle biopsies performed within a year, because of a lack of a clear diagnosis. In summary, the latter two biopsies, reported by the same neuropathologist, indicated no evidence of an inflammatory myopathy but was otherwise non diagnostic. Because Pompe was not considered by three of these clinicians in the differential diagnosis, acid maltase staining was not performed and the diagnosis missed. The fourth neurologist assessed the patient with this presentation and the diagnosis of Pompe was considered.

Past medical history included hypertension, gastroesophageal reflux, treated hypothyroidism and a longstanding myopathy. Sensorineural hearing loss was diagnosed at age 38 and required hearing aids. She was not on a statin and there was no family history of muscle disease.

In the ER the patient was tetraparetic and dyspneic at rest sitting up. She decompensated overnight into a state of hypercapnic respiratory failure with somnolence. Blood gases revealed a PH of 7.15, PCO_2 134, PO_2 85 and HCO_3 44 before decompensation, suggestive of acute on chronic respiratory acidosis. Spirometry upright revealed an FVC of 31% with an FEV 1 of 37%, and a normal FEV 1/FVC ratio of 97%, suggestive of severe restrictive lung disease. A chest x-ray was normal. A CPK at presentation was normal, probably related to decreased muscle mass. Previously, CPK's were modestly elevated, range 139-194u/L(n30-135ul). Electromyography demonstrated abundant complex repetitive discharges, fibrillations and chronic myopathic units.

The patient was subsequently admitted to Intensive Care over the next month and was managed with non invasive ventilation, primarily Bi-Pap. During the admission a diagnosis of Pompe Disease was confirmed with investigations including DBSs (GAA activity was absent - Mayo Clinic) and reduced in a second DBS study. Enzyme analysis on cultured fibroblast was 2% of normal. Additionally genetic testing and elevated urinary Glc4 were consistent with a diagnosis of Pompe Disease.

Two muscle biopsies done within the previous five years were reviewed. A large amount of glycogen was found on PAS stained frozen sections. Electron microscopy showed that the glycogen was both free and membrane bound. No structural abnormalities were noted in the glycogen granules. (Fig. 1).

Subsequent genetic testing with GAA sequencing revealed two

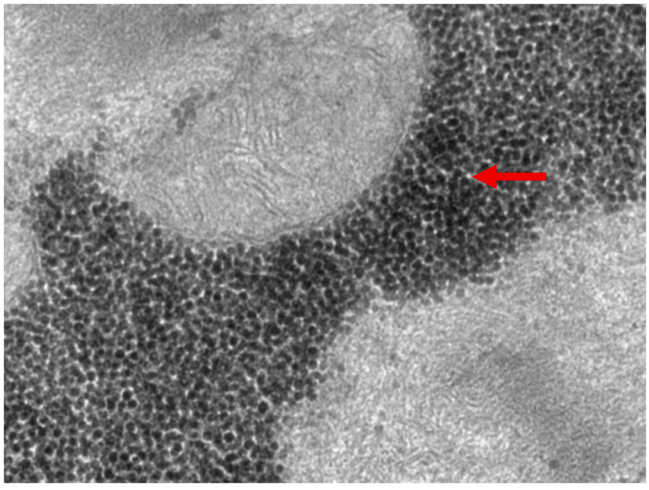

Fig. 1. EM muscle biopsy stained with Uranyl-lead showed abundant normal glycogen between muscle fibres (arrow).

pathogenic variants both reported in other cases of Pompe Disease, and subsequent family testing showed these variants were in *trans* as was expected from the various biochemistry results. The first variant was GAA(NM_001079804.3):c.-32-13 T > G. The second variant in the patient was GAA(NM_001079804.3):c.2242dup(p.Glu748GlyfsTer48).

Other relevant investigations during this admission included a normal echocardiogram, several normal EKG's and CPK's that were within the normal range or modestly increased. Glc4 6.6 mmol/mol creatinine (reference range < 3.0).

3. Course on ERT

The patient was discharged from ICU after a month stay on long term nocturnal Bi-Pap. She was wheelchair dependant but with 2 person assistance to stand and could walk a few steps with a walker. Limb strength then demonstrated profound proximal weakness with abductors of the arm grade 4^{-} on the MRC Scale, and flexors of the thigh grade 2. Distally in both lower extremities power was grade 4 to 4+. One and a half years after diagnosis, ERT was started - Myozyme dose 20mg/kg q 2 weeks. The patient has been maintained on this regime to the present time with over five years of Myozyme treatment.

At two years on treatment the patient was assessed and power was now grade 4 proximally in the arms, and grade 3 proximally in the legs with knee extension 4+. Once in the standing position, after pushing up with her arms, she was able to slowly mobilize independently with a cane 500 m. This patient lives alone in a three storey building and could slowly climb stairs from the basement to her living room (9 stairs), using both rails, and from the living room to her bedroom on the third floor (13 stairs). She was self sufficient in terms of her ADL's and lived alone, and continues to do so to the present. The patient reported over the last five years, that the Canadian Association of Pompe was a great source of support for herself and family, in many different forms including patient literature, in-person and social media support group meetings.

At four years the patient's six minute walk test was 59.13 m. Presently at 5 year, she still lives independently with the use of a cane or walker for walking distances. Formal assessment of strength was arm abductors 4+, hand grips 4+; hip flexor 3, extensor of knees and ankle dorsiflexion 4+. She remains on BiPAP at night. Over time, it was observed that the restrictive pattern and reduced FVC stabilized after initial modest improvement with ERT (see Fig. 2). PaCO2 improved markedly after initiation of NIV though continuing to show mild but chronic stable elevation with compensation on ERT; PH remained in the normal range (Fig. 3).

Antibody titres converted from negative to positive after two years, increasing from an antibody titre of 100 at year 2 to 200 at year 4.

4. Discussion

The diagnosis of Pompe Disease was confirmed via biochemistry with further confirmation with genetic testing of GAA sequencing. This revealed the two pathogenic variants already described. One variant results in a premature codon and due to nonsense mediated decay results in haploinsufficiency [1–34]. This variant has been reported repeatedly in the literature with Pompe's patients including LOPD. This variant is relatively high, 1:95 [19]. The other variant (c.-31-13 T > G) is the most common variant associated with LOPD and leads to abnormal splicing, albeit with the generation of a small amount of functional transcript, and the latter relative preservation of function is likely why this variant has not been reported in infantile Pompe Disease [20]. The variant in Northern Europeans is relatively high at 1:94 person [19].

Our patient was diagnosed and managed in a community hospital setting, and illustrated many of the typical problems and challenges faced in making the diagnosis of LOPD, which have been previously noted in the literature. These include: 1) a long duration to diagnosis (three decades in this case) [1,7,19,20]. 2) initial mis-diagnosis over three decades, seen in up to 50% of cases, and generally associated with missed or mis-diagnosis [4,9,21,22]. 3) The frequent involvement of neurologists in missed diagnosis [21,23]. With regards to LOPD however, there is a suggestion that both earlier diagnosis and treatment may be beneficial to patient outcome [14], thus emphasizing the need for more timely diagnosis. In our case the diagnosis was clear within months with enzyme testing and review of previous muscle biopsies.

The problem of mis-diagnosis and the inordinately long time for diagnosis can be best addressed by increased familiarity by neurologists

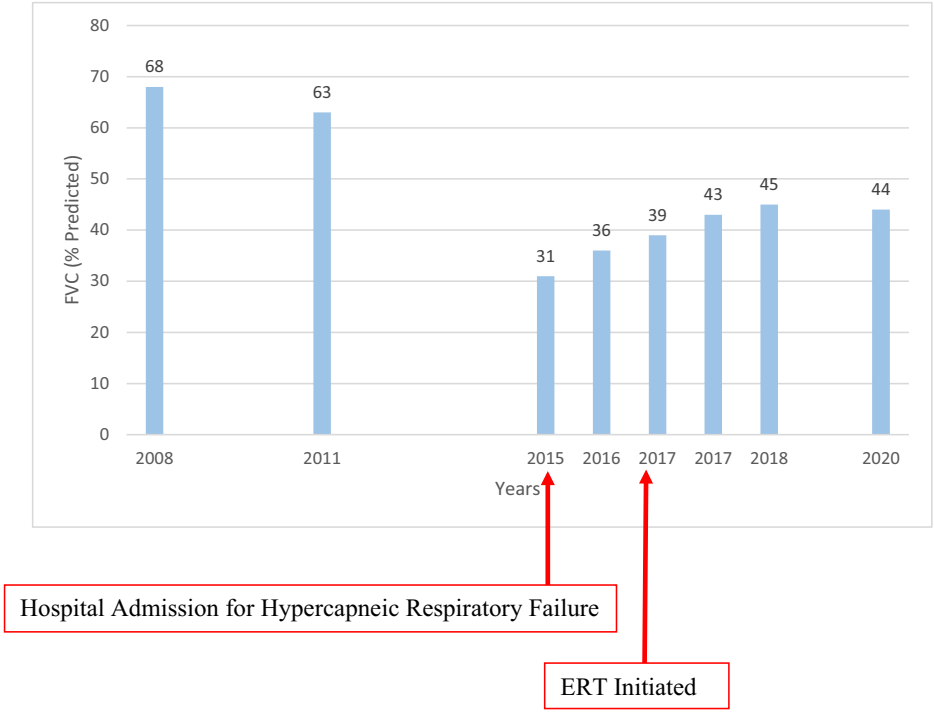

Fig. 2. Forced Vital Capacity (FVC) measurements.

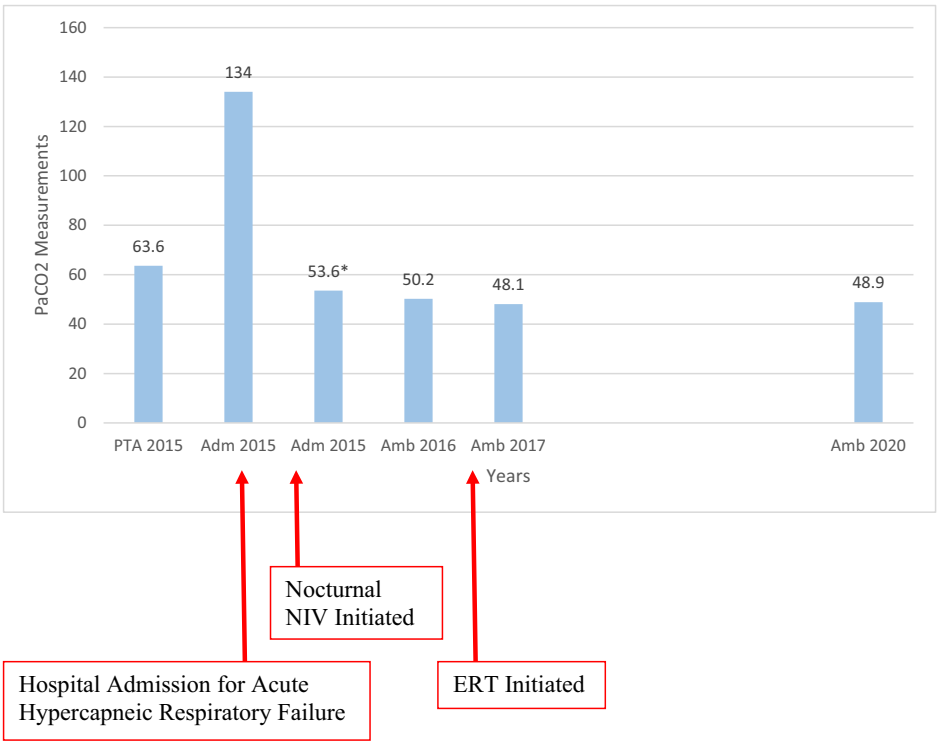

Fig. 3. PaCO2 measurements.
PTA 2015 = PaCO2 Measurement prior to 2015 Hospital Admission room air; Adm 2015 = Emergency Room PaCO2 Measurement during 2015 Hospital Admission; Amb 2017 = Ambulatory PaCO2 Measurement in 2017; Amb 2020 = Ambulatory PaCO2 Measurement in 2020; NIV = Noninvasive Ventilation; ERT = Enzyme Replacement Therapy. *Performed on day 7 of 2015 hospital admission.

of the phenotypic clinical presentation of Pompe disease. In years ahead, the ability to apply next generation sequence myopathy panels in a routine fashion to such cases, may lead to early diagnosis. Therefore going forward, as in this case, a true diagnosis will require ongoing assessment as to whether the clinical course fits with the genetic diagnosis or whether alternative diagnoses (including potentially non genetic etiologies) need to be considered by clinicians without specific training in genetic or metabolic diseases. Educational tools from academic and perhaps pharmaceutical companies may also be helpful.

LOPD phenotypic presentation is that of a progressive limb girdle type weakness affecting legs, trunk and respiratory muscles resulting in respiratory symptoms and is the most common presentation in up to 80% of cases [1–3,22]. Progressive respiratory weakness without obvious cause or obvious correlation to degree of limb girdle weakness also constitutes a phenotypic presentation that requires consideration of LOPD [6,22,24,25]. Presentations of acute hypercapnic respiratory failure without notable mobility issues, as in our case, has been described [6,21,22,24,26]. Importantly morbidity and mortality are related to degree of muscle weakness and respiratory impairment, with respiratory failure being the most frequent cause of death [3,25]. In untreated LOPD, approximately two thirds of patients show simultaneous decline in MRC score and respiratory function. Respiratory dysfunction develops in approximately two thirds of Pompe patients with a mean annual decline in VC of about 1.6% [27], as opposed to the modest improvement and subsequent stabilization on ERT as in our case. Long term ERT has been shown previously to lead to some improvement in FVC in LOPD [12,28].

There is a relatively short list of differential diagnoses for the typical phenotypic presentation noted above, which includes limb girdle dystrophies, rigid spine syndrome, myasthenia gravis, other glycogen storage diseases, mitochondrial myopathies, and polymyositis [22].

Our case presented with advanced disease and severe symptoms, i.e., the patient was wheelchair dependant with acute hypercapnic respiratory failure. There was uncertainty in the managing clinician's mind about the role of ERT in managing this particular patient. There is no RCT data to support the use of ERT in this patient group. Expert opinion generally suggests ERT to be "considered" in these patients with the requirement of monitoring [16,17]. A single case report similar to ours demonstrated significant motor improvement and respiratory stability after two years of ERT, with return of mobility from a wheelchair dependant state [29]. There are open label case series and observational studies from 4 to 10 years of ERT, which do include patients with severe symptoms as a small group. Generally, these reports demonstrate improvement and/or stabilization of motor and respiratory function in up to two thirds of patients, with increased survival; A meta-analysis showed up to five-fold lower mortality in these patients treated as a group [14,25,28,31]. However, there are patients in this advanced group who progress, some to death, usually from a respiratory cause [25,28,30,31]. A French longitudinal study over a median of 55 months and a median age 53 of advanced LOPD on ERT, showed stability or slight improvement, with a 42% mortality [25]. There is also the suggestion of late decline in benefit, in LOPD after three to five years of ERT [15,28], hence the need for ongoing clinical monitoring [30]. A recent observational study demonstrated a positive impact of ERT on quality-of-life measures in LOPD, which included up to 50% of patients with severe symptoms and a median follow-up of four years (range 0.5–8) [32]. This latter finding adds further weight to recommendations that suggest "offering" ERT to severe LOPD patients.

Our case demonstrated stability of respiratory function, and return of mobility after four years with a 6MWT of 59.13 m at her last follow-up. These findings are in line with the expected benefit from ERT from a systematic review and meta-analysis [14]. These findings are also consistent with the evolving literature on LOPD patients with severe symptoms, and use of ERT in their management [25,31–33]. Therefore, like other authors, we also recommend that all patients with slowly progressive limb girdle and/or respiratory muscle weakness be screened with DBS for Pompe Disease [7,8,10], with confirmatory testing including genetic testing [7,8]. Further, we agree that with positive testing for Pompe including genetic testing, muscle biopsies are not required [7–9]. Finally, the present yearly cost for Myozyme therapy in Canada is expensive [34], which requires judicious decision making on ERT use in LOPD patients such as our case. Our case report of continuous

ERT use over 5 years supports expert opinion of "considering" ERT in LOPD with severe symptoms, with close follow-up to determine longitudinal benefit.

Data availability

Data will be made available on request.

References

[1] L. Kohler, R. Puertollano, N. Raben, Pompe Disease: From Basic Science to Therapy Neurotherapeutics 15, 2018, pp. 928–942.
[2] M. Dasouki, O. Jawdat, O. Almadhoun, et al., Pompe disease: literature review and case series, Neurol. Clin. 32 (3) (2014 August) 751–756, ix.
[3] D. Gungor, J.M. de Vires, W.C.J. Hop, et al., Survival and associated factors in 268 adults with Pompe disease prior to treatment with enzyme replacement therapy, Orphan. J. Rare Dis. 6 (2011) 34.
[4] C. Angelini, Spectrum of metabolic myopathies, Biochim. Biophys. Acta 2015 (1852) 615–621.
[5] M.G.E.M. Ausems, J. Verbiest, Hermans MMP, et al., Frequency of glycogen storage disease type II in the Netherlands: implications for diagnosis and genetic counselling, Eur. J. Hum. Genet. 7 (1999) 713–716.
[6] A.T. Van der Ploeg, A.J.J. Reuser, Lysomal storage disease 2 Pompe's disease, Lancet 372 (2008) 1342–1353.
[7] B.K. Burton, D.F. Kronn, W.-L. Hwu, et al., The initial evaluation of patients after positive newborn screening: recommended algorithms leading to a confirmed diagnosis of Pompe disease, Paediatrics 140 (Suppl1) (2017 Jul) S14–S23.
[8] P.S. Kishnani, H.M. Amartino, C. Lindberg, et al., Methods of diagnosis and patients with Pompe disease: data from the Pompe registry, Mol. Genet. Metab. 113 (2014) 84–91.
[9] A. Genge, N. Campbell, Reevaluating muscle biopsies in the diagnosis of Pompe disease: a Corraborative report, Can. J. Neurol. Sci. 43 (2016) 561–566.
[10] J.L. Goldstein, S.P. Young, M. Changela, et al., Screening for Pompe disease using a rapid dried blood spot method: experience of a clinical diagnostic laboratory, Muscle Nerve 40 (2009) 32–36.
[11] P.S. Kishnani, Nicolino M. Corzo, et al., Recombinant human acid (alpha) - glucosidase: Major clinical benefits in infantile-onset Pompe disease, Neurology 68 (2) (2007 Jan 9) 99–109.
[12] A.T. van der Ploeg, P.R. Clemens, D. Corzo, et al., A randomized study of alglucosidase alpha in late-onset Pompe's disease, N. Engl. J. Med. 362 (2010) 1396–1406.
[13] A.T. van der Ploeg, R. Richard Barohn, L. Carlson, et al., Open-label extension study following the late-onset treatment study (LOTS) of alglucosidase alfa, Mol. Genet. Metab. 107 (2012) 456–461.
[14] B. Schoser, A. Stewart, S. Kanters, et al., Survival and long-term outcomes in late-onset Pompe disease following alglucosidase alfa treatment: a systematic review and meta-analysis, J. Neurol. 264 (2017) 621–630.
[15] E. Kuperus, M.E. Kruijshaar, S.C.A. Wens, Long-term benefit of enzyme replacement therapy in Pompe disease: a 5-year prospective study, Neurology 89 (23) (2017) 2365–2373.
[16] M. Tarnopolsky, H. Katzberg, B.J. Petrof, et al., Pompe disease: diagnosis and management. Evidence-based guidelines from a Canadian expert panel, Can. J. Neurol. Sci. 43 (2016) 472–485.
[17] E.J. Cupler, Berger Kl, R.T. Leshner, et al., Consensus treatment recommendations for late-onset Pompe disease, Muscle Nerve 45 (3) (2012 March) 319–333.
[18] M. Kroos, M. Hoogeveen-Westerveld, H. Michelakakis, et al., Update of the pompe disease mutation database with 60 novel GAA sequence variants and additional studies on the functional effect of 34 previously reported variants, Hum. Mutat. 33 (8) (2022) 1161–1165.
[19] K.J. Karczewski, L.C. Francioli, G. Tiao, The mutational constraint spectrum quantified from variation in 141,456 humans, Nature Vol. 581 (2020) 434–443, https://doi.org/10.1038/s41586-020-2308-7.
[20] A. Dardis, I. Zanin, S. Zampieri, et al., Functional characterization of the common c.-32-13T>G mutation of GAA gene: identification of potential therapeutic agents, Nucleic Acids Res. 42 (2) (2014) 1291–1302.
[21] G.K. Papadimas, K. Spengos, C. Papadopoulos, et al., Late onset glycogen storage disease type II: Pitfalls in the diagnosis, Eur. Neurol. 67 (2012) 65–68, https://doi.org/10.1159/000334398.
[22] C. Chan, A.K. Desai, Z.B. Kazi, et al., The emerging phenotype of late-onset Pompe disease: a systematic literature review, Mol. Genet. Metab. 120 (2017) 163–172.
[23] L.D. Hobson-Webb, P.S. Kishnani, How common is misdiagnosis in late-onset Pompe disease? Muscle Nerve 45 (2) (2012 Feb) 301–302.
[24] N. Preisler, Z. Lukacs, L. Vinge, et al., Late-onset Pompe disease is prevalent in unclassified limb-girdle muscular, Mol. Genet. Metab. 110 (2013) 287–289.
[25] C. Papadopoulos, D. Orlikowski, H. Prigent, et al., Effect of enzyme replacement therapy with alglucosidase alfa (Myozyme) in 12 patients with advanced late-onset Pompe disease, Mol. Genet. Metab. 122 (2017) 80–85.
[26] F. Menzella, L. Codelupp, M. Lusuardi, et al., Acute respiratory failure as presentation of late-onset Pompe disease complicating the diagnostic process as a labyrinth: a case report, Multidiscip. Respir. Med. 13 (2018) 32.
[27] N.A. Van der Beek, M.L. Hagemans, A.J. Reuser, et al., Rate of disease progression during long term follow-up of patients with late onset Pompe disease, Neuromuscul. Disord. 19 (2) (2009 Feb) 113–117, https://doi.org/10.1016/j.nmd.2008.11.007.
[28] A. Toscano, B. Schoser, Enzyme replacement therapy in late onset Pompe disease: a systemic literature review, J. Neurol. 260 (2013) 951–959.
[29] L. Case, D.D. Loeberl, S.P. Young, et al., Improvement with ongoing enzyme replacement therapy in advanced late-onset Pompe disease: a case study, Mol. Genet. Metab. 95 (2008) 233–235.
[30] L. Harlaar, J.-Y. Hogrel, B. Perniconi, Large variation in effects during 10 years of enzyme therapy in adults with Pompe disease, Neurology 93 (2019) e1756–e1767.
[31] K.M. Stepien, J. Christian, C.J. Hendriksz, M. Roberts, Observational clinical study of 22 adult-onset Pompe disease patients undergoing enzyme replacement therapy over 5 years, Mol. Genet. Metab. 117 (2016) 413–418.
[32] D. Deniz Gungor, M.E. Kruijshaar, Plug I Quality of life and participation in daily life of adults with Pompe disease receiving enzyme replacement therapy: 10 years of international follow-up, J. Inherit. Metab. Dis. 39 (2016) 253–260, https://doi.org/10.1007/s10545-015-9889-6.
[33] Y. Furusawa, M. Movi-Yoshimura, T. Yamamoto, Effect of enzyme replacement therapy on five patients with advanced late onset glycogen storage disease type II: a 2 year follow-up study, J. Inherit. Metab. Dis. 35 (2012) 301–310.
[34] Saskatchewan Ministry of Health, Formulary, Sixty-Second edition, Ministry of Health Government of Saskatchewan, Regina, 2022, p. 221.